
Stability of early Class III orthopedic treatment

Erica Reed, DDS, MS, Thomas J. Kiebach, DDS, Chris Martin, DDS, MS, Thomas Razmus, DDS, MS, Erdogan Gunel, PhD, and Peter Ngan, DMD

The objective of the article is to determine the stability of early Class III orthopedic treatment in the primary and early mixed dentitions. A total of 23 patients with Class III malocclusion in the primary or early mixed dentition (mean age = 6.2 ± 1.5 years, CVM = 1) were treated consecutively by one of the investigators (T.K.) using maxillary expansion and protraction appliances. The average treatment time was 9.1 ± 2.3 months. For each patient, a lateral cephalogram was taken at pre-treatment (T1), post-treatment (T2), and 2 years post-treatment (T3). Each patient served as his/her own control. Cephalometric analysis described by Bjork (1947) and Pancherz (1982) was used. Sagittal and vertical measurements were made along the occlusal plane (OLs) and the occlusal plane perpendicular (Olp), and superimposed on the mid-sagittal cranial structure. Data were analyzed using paired t-test. All patients in the study were treated to Class I or overcorrected to Class II dental arch relationships. Overjet and sagittal molar relationships improved by an average of 4.1 and 1.8 mm, respectively (T2–T1). This was a result of 2.6 mm of forward maxillary growth, .7 mm of forward mandibular growth, 1.2 mm of labial movement of maxillary incisors, 1.0 mm of lingual movement of mandibular incisors, and .1 mm of greater mesial movement of mandibular than maxillary molars. The mean overbite reduction was .9 mm. The maxillary and the mandibular molars were erupted occlusally by 1.5 and 1.0 mm, respectively. The mandibular plane angle was increased by $.9^\circ$ and the lower facial height by 3.2 mm. Overall, 2 years follow-up observation (T3–T2) revealed a decrease in the overjet and the molar relationship by .3 and .2 mm, respectively. This was contributed by 2.2 mm of excess forward mandibular growth that was compensated by 1.9-mm dentoalveolar compensation. Overall, the changes in the overjet and the molar relationship were 3.8 and 1.5 mm, respectively. The overbite reduction was .6 mm. Significant overjet and overbite corrections can be obtained with maxillary protraction in the primary or early mixed dentition. Overjet and molar relationship corrections were stable 2 years post-treatment. A combination of dentoalveolar compensation and skeletal changes accounted for this stability. (Semin Orthod 2014; 20:114–127.) © 2014 Elsevier Inc. All rights reserved.

Private practice, White Oak, PA; Private practice, Baton Rouge, LA; Department of Orthodontics, West Virginia University School of Dentistry, Morgantown, WV; Department of Periodontics, University of Michigan School of Dentistry, Ann Arbor, MI; Department of Statistics, West Virginia University, Morgantown, WV.

Address correspondence to Peter Ngan, DMD, 1073 Health Science Center North, P.O. Box 9480, Morgantown, WV 26506. E-mail: pngan@hsc.wvu.edu

© 2014 Elsevier Inc. All rights reserved.

1073-8746/12/1801-\$30.00/0

<http://dx.doi.org/10.1053/j.sodo.2014.04.003>

Introduction

Maxillary protraction has been shown to be effective in the treatment of Class III patients with maxillary deficiency. The recommended age to begin treatment is between the age of 6 and 8 years after the maxillary permanent first molars and incisors have erupted.^{1–3} Studies that employed biologic indicators such as chronological age, stage of dental development, or skeletal age to determine the impact of age on orthopedic treatment found younger patients

more responsive to orthopedic correction.^{1,4-10} Compared to permanent dentition treatment, advantages of earlier orthopedic treatment include more consistent patient (and parent) compliance, less patient discomfort, and no loss of root structure or caries that may be present in the permanent dentition.⁵⁻¹⁰

Various appliances have been used as anchorage devices for maxillary protraction. Typically, a heavy .036-in wire is usually soldered to the buccal side of the molar band and extends forward to the canine area for protraction.⁶ This may present solder joint failure issues leading to compliance problems. A new design that utilizes a stainless steel crown and a removable arm for maxillary protraction may overcome this problem (Fig. 1). This arm resists deformation and fracture while also providing rigidity. The stainless steel crowns keep the anterior teeth away from occlusion. This design is particularly suitable for patients in the primary and early mixed dentitions. The objective of this study was to determine the stability of early Class III orthopedic treatment using this new anchorage design.

Methods and materials

Experimental design and methods

The sample consisted of before, after, and 2 years after treatment using lateral cephalograms of 23 patients in the primary and early mixed dentitions treated with maxillary expansion and protraction facemask. The Cervical Vertebra Maturation (CVM) for all subjects was an average of CVM 1.0. The mean age at the start of treatment was 6.2 ± 1.5 years with a range of 4 years 4

months to 10 years 4 months. The average treatment time was 9.1 ± 2.3 months.

Appliances for Class III correction

The Hyrax rapid palatal expansion appliance was constructed by using stainless steel crowns fitted on the maxillary second primary molars. These crowns were joined by a heavy wire (.043 in) to the palatal plate, which had a jack screw in the midline. The appliance was activated twice daily (.025 mm per turn) by the patient for 1 week. In patients with a constricted maxilla, activation of the expansion screw was applied for 2 weeks. A headgear tube was welded on the buccal surface of the stainless steel crowns. Removable arms were fitted to the headgear tube, extended to the canine area with a hook for maxillary protraction (AOA Orthodontic Appliances, Sturdevant, WI). Removable arms were secured with separators. The facemask was a one-piece construction with an adjustable anterior wire and hooks to accommodate a downward and forward pull of the maxilla with elastics. In order to reduce bite opening during forward maxillary repositioning, the protraction elastics were attached near the maxillary canines with a downward and forward pull of 30° to the occlusal. Depending on the individual patient treatment response, maxillary sutural protraction may require 300–600g per side. For this study, elastics delivering 400g of force per side were used. A strain gauge was used to assess elastic pressure levels, and patients were instructed to wear the facemask 12 h a day.

Cephalometric analysis

For each patient, the first lateral cephalogram was taken pre-treatment (T1). A second radiograph

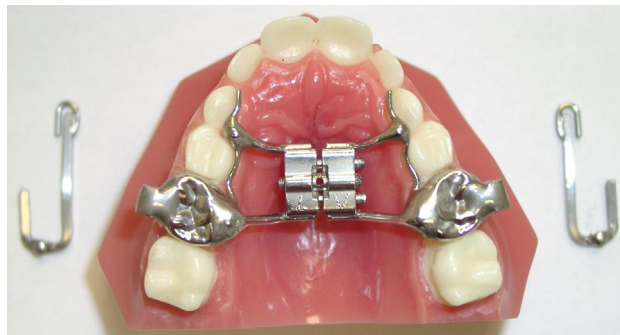

Figure 1. Maxillary expansion appliance with stainless steel crowns on the maxillary primary second molars and removable arms extended to the canine area for maxillary protraction. (Courtesy Dr. Tom Kiebach.)

was taken immediately after removal of the appliance (T2), and a third radiograph was taken after 2 years of observation (T3). The radiographs were digitized in Dolphin Imaging (Dolphin Imaging, Chatsworth, CA) and adjusted for magnification. Each image was then printed 1:1 to ensure there was no magnification. The files were printed on an Epson Stylus Pro 3880 printer on quality photo paper (HP Premium Photo Paper). All landmarks and tracings were made on the printouts while viewing the original digital file. Tracings were performed by an operator using a .5-mm mechanical lead pencil, an orthodontic protractor, and a .003-in matte cephalometric acetate tracing film. Custom cephalometric analysis was performed as described by Bjork¹¹ and Panchez.¹²

All radiographs used in the present study were taken using the same cephalostat with the teeth in habitual occlusion. The cephalometric system used in this study has been described by Bjork and Panchez, and the landmarks used are defined in Figs. 2–5. The analysis of sagittal and dental changes was recorded along the occlusal plane (OLs) and to the occlusal plane perpendicular (OLp) from the first cephalogram, which formed the reference grid for all the sagittal and vertical measurements. The grid was then transferred to the second cephalogram by superimposing the tracing on the mid-sagittal cranial structure. All sagittal measurements were assessed and recorded twice with electronic digital calipers to the nearest .1 mm.

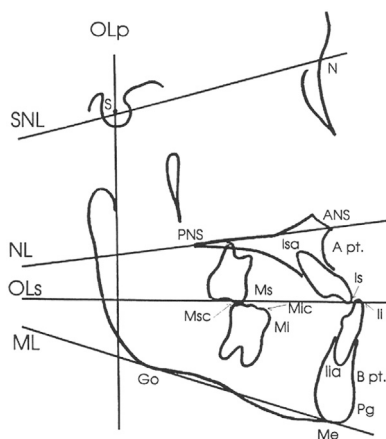


Figure 2. Skeletal and dental landmarks.

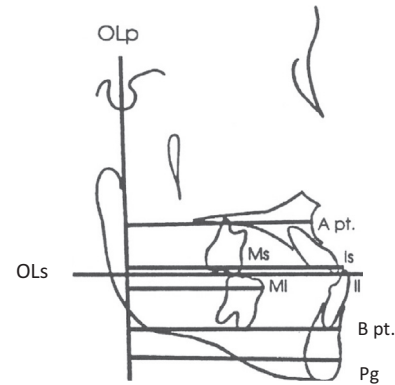


Figure 3. The reference grid (OLs and OLp) and measuring points used in the sagittal cephalometric analysis.

Statistical analysis

A paired *t*-test was used to compare T1 to T2, T2 to T3, and T1 to T3. This was used on each variable to identify the overall treatment effects of the Modified Hyrax Expander in combination with protraction facemask treatment. A level of significance of $P < .05$ (95% confidence interval) was used in this study.

In order to obtain the coefficient of reliability, a measurement was made on the initial tracing and another measurement was made on the same tracing 2 weeks later. When there are two measurements, the coefficient of reliability is the correlation coefficient of the first and second measurements. Correlation coefficients were reported to determine how strongly the first

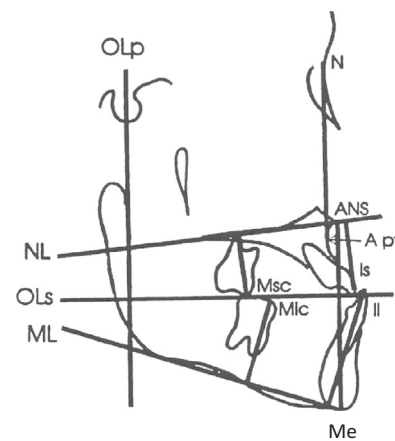


Figure 4. The reference lines and measuring points used in the vertical cephalometric analysis.

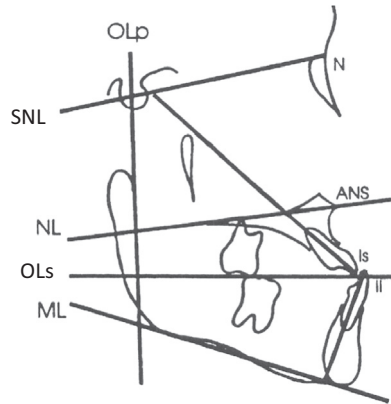


Figure 5. The reference lines and measuring points used for angular cephalometric analysis.

measurements were associated with the second measurements of each variable at every time period in six individuals. The method of cephalometric analysis used in this study was determined to be reliable (Table 1). This included the identification of landmarks, superimposition of radiographs, and the measurements taken at

Table 1. Reliability Coefficients for All Variables at T1, T2, and T3

Variables	Reliability
Sagittal	
OLp-A	.98
OLp-Pg	.96
Is-OLp	.99
Ii-OLp	.98
Overjet	.88
Ms-OLp	.98
Mi-OLp	.95
Molar relationship	.75
Vertical	
N-A	.95
ANS-Me	.96
Is-NL	.97
Ii-ML	.95
Overbite	.91
Msc-NL	.97
Mic-ML	.96
Angular	
SNA	.80
SNB	.92
ANB	.88
SNL-NL	.93
SNL-ML	.94
SNL-OLs	.95
Is/SNL	.97
Ii/ML	.97
Is/Ii	.97

each time point. Reliability ranged from .75 to .99, which means that the method of data collection was reliable.

Evaluation of overjet and molar relationship correction

To determine the amount of skeletal and dental contribution to the overjet and the molar relationship correction, the amount of dental change in the maxilla and mandible was calculated. The method of obtaining these measurements is shown in (Table 2).

When adding figures from Table 2, the following formula was used for overjet correction:

$$\text{Overjet Correction} = \text{Maxilla} + \text{Mx incisor} - \text{Mandible} - \text{Md incisor}$$

$$\text{Maxilla} = \text{OLp-A pt.}$$

$$\text{Mx incisor} = \text{Is-OLp minus OLp-A pt.}$$

$$\text{Mandible} = \text{OLp-Pg}$$

$$\text{Mandibular incisor} = \text{Ii-OLp minus OLp-Pg}$$

When adding figures from Table 2, the following formula was used for molar relationship correction or increase:

$$\text{Molar Relationship Correction} = \text{Maxilla} + \text{Mx Molar} - \text{Mandible} - \text{Md Molar}$$

$$\text{Maxilla} = \text{OLp-A pt.}$$

$$\text{Maxillary molar} = \text{Ms-OLp minus OLp-A pt.}$$

$$\text{Mandible} = \text{OLp-Pg}$$

$$\text{Mandibular molar} = \text{Mi-OLp minus OLp-Pg}$$

Table 2. Calculation of Overjet and Molar Relationship Changes

Overjet	Molar Relationship
Skeletal contributions	
1. OLp-Apt	1. OLp-Apt
2. OLP-Pg	2. OLP-Pg
Dental contributions	
3. Is-OLp minus OLp-Apt	3. Ms-OLp minus OLp-Apt
4. Ii-OLp minus OLp-Pg	4. Mi-OLp minus OLp-Pg
Overjet correction	Molar relationship correction
Sum of 1, 2, 3, and 4	Sum of 1, 2, 3, and 4

Table 3. Cephalometric Measurements

Variable	T1				T2				T3			
	Mean	S.D.	Min	Max	Mean	S.D.	Min	Max	Mean	S.D.	Min	Max
Sagittal												
Ol-p-A pt.	63.81	4.79	56.5	74.45	66.45	4.86	59.17	79.5	68.00	5.13	60	78.9
Ol-p-Pg	67.79	5.51	59.6	79.33	68.46	6.28	58.75	82.5	72.20	6.64	59.1	89.8
Is-Olp	66.54	6.46	58.5	83.98	70.34	7.12	61	90.68	73.68	7.77	58.78	90.92
Ii-Olp	68.45	6.52	60.22	86.55	68.12	6.89	58.68	86.9	71.79	6.67	61.2	86.47
Overjet	-1.90	1.33	-4.37	2.2	2.22	1.40	-0.95	5.1	1.93	1.89	-2.42	4.45
Ms-Olp	39.15	5.51	32	51.58	42.10	4.59	35.62	53.3	44.96	5.70	36	56.26
Mi-Olp	41.59	5.25	34.27	55.05	42.83	5.16	36.84	54.3	45.92	5.72	38	58.26
Molar relationship	-2.39	1.49	-5.05	.6	-.72	2.23	-5.75	3.8	-.96	1.79	-4.56	3.5
Wits	-4.2	1.9	-8.4	.0	-1.0	2.9	-7.1	4.4	-2.5	2.0	-6.8	1.7
Vertical												
Nasion-Apt	44.18	3.14	40.53	50.8	46.55	3.60	41	56.26	49.86	3.69	42.8	60
ANS-Me	52.87	4.56	44.75	63.67	56.08	5.96	46.71	70.23	56.85	5.61	46.85	68.23
Is-NL	22.26	3.27	17.61	31.32	23.59	4.06	18.23	35.4	24.61	3.91	18.73	33.59
Ii-ML	33.07	3.22	28.74	41.64	34.37	3.70	29.13	44.37	35.81	3.56	29.09	44.55
Overbite	1.98	1.61	-1.57	4.31	1.02	1.39	-2.2	2.95	1.42	1.70	-1.2	4.11
Msc-NL	14.11	2.25	10.86	19.4	15.61	2.81	12.3	24.6	16.12	2.79	11.12	23.56
Mic-ML	21.75	2.59	18.94	30.43	22.75	2.86	18.2	30.33	24.02	2.79	19.63	31.55
Angular												
SNA	80.39	4.33	70	90	80.78	3.86	75	86	80.17	3.96	74	87
SNB	80.56	4.28	72	91	78.82	3.98	70	85	79.30	3.37	72	85
ANB	-.26	2.24	-4	6	1.91	2.06	-3	5	.73	2.61	-4	9
SNL-NL	7.30	3.92	1	17	7.39	3.61	3	16	8.04	3.72	2	18
SNL-ML	32.08	3.67	26	39	33.04	4.18	25	42	31.26	4.35	25	39
SNL-Ols	15.78	4.26	9	24	16.04	3.58	9	25	15.95	3.94	9	23
Is/NL	93.60	9.28	80	113	96.95	8.48	85	113	103.43	9.35	88	120
Ii/ML	87.13	6.67	82	106	85.21	7.61	71	102	90.39	10.12	74	115
Interincisal angle	148.08	10.22	120	159	145.87	13.50	120	170	136	12.81	117	161

Results

Cephalometric measurements

Measurements for each of the 25 variables were analyzed. The mean, standard deviation, and maximum and minimum for each variable measurement were recorded for each time period (T1, T2, and T3). [Table 3](#) shows the sagittal, vertical, and angular measurements at time periods T1, T2, and T3.

Cephalometric changes of T2–T1, T3–T2, and T3–T1

Changes of cephalometric measurements for patients treated with protraction headgear before treatment (T1), after treatment (T2), and 22 months after removal of the appliance (T3) are shown in [Table 4](#). Of the 25 variables investigated, significant changes were found in most variables.

[Figs. 6–8](#) summarize the changes during treatment for T2–T1. The overjet and the sagittal

molar relationships improved by an average of 4.1 and 1.8 mm, respectively. Looking at [Table 4](#), seven out of nine sagittal measurements were significant. The non-significant measurements were OLp-Pg and Ii-OLp. This means that Pogonion did not have a significant change between time points T2 and T1. The lower incisor inclination was also non-significant. Vertical changes included an overbite decrease of .96 mm. This decrease in overbite was due to primary teeth being exfoliated and permanent central incisors erupting during treatment. It could also have been due to the Stainless Steel Crown used in the Modified Hyrax Expander. As the patients wore the facemask, the maxilla grew downward and forward while the mandible grew vertically. Only four out of the nine measurements for the angular section were statistically significant. The four that were statistically significant were SNB, ANB, Is/SNL, and Ii/ML. This shows that the mandibular prominence changed significantly between T2 and T1 measurements. Also, the maxillary incisor angulation

Table 4. Comparison of T2–T1, T3–T1, and T3–T2

Variable	T2–T1				T3–T2				T3–T1			
	Mean	S.D.	P Val	sig	Mean	S.D.	P Val	sig	Mean	S.D.	P Val	sig
Sagittal												
Olp-A	2.6	1.5	.0001	*	1.5	2.0	.0014	*	4.2	2.3	.0001	*
Olp-Pg	.6	2.7	.2571	NS	3.7	3.6	.0001	*	4.4	4.4	.0001	*
Is-Olp	3.8	2.4	.0001	*	3.3	3.1	.0001	*	7.1	4.1	.0001	*
Ii-Olp	–.3	2.5	.5371	NS	3.6	3.1	.0001	*	3.3	3.7	.0003	*
Overjet	4.1	2.1	.0001	*	–.3	1.7	.4374	NS	3.8	2.4	.0001	*
Ms-Olp	2.9	2.7	.0001	*	2.8	2.7	.0001	*	5.8	3.3	.0001	*
Mi-Olp	1.2	2.1	.0083	*	3.1	3.2	.0002	*	4.3	3.5	.0001	*
Molar rel	1.6	2.0	.0007	*	–.2	1.6	.4860	NS	1.4	1.7	.0008	*
Wits	3.1	2.6	.0001	*	1.6	2.5	.0049	*	–1.4	2.4	.0121	*
Vertical												
N-A	2.3	2.3	.0001	*	3.3	2.2	.0001	*	5.7	2.7	.0001	*
ANS-Me	3.2	2.7	.0001	*	.7	2.6	.1733	NS	4.0	2.1	.0001	*
Is-NL	1.3	1.5	.0004	*	1.0	2.0	.0251	*	2.3	2.0	.0001	*
Ii-ML	1.3	1.2	.0001	*	1.4	1.2	.0001	*	2.7	1.1	.0001	*
Overbite	–.9	1.7	.0150	*	.4	1.7	.2548	NS	–.6	1.9	.1659	NS
Msc-NL	1.4	1.6	.0002	*	.5	1.8	.1886	NS	2.0	1.3	.0001	*
Mic-ML	1.0	1.4	.0035	*	1.3	1.4	.0003	*	2.3	1.6	.0001	*
Angular												
SNA	.4	2.5	.4671	NS	–.6	2.2	.2002	NS	–.2	2.5	.6833	NS
SNB	–1.7	2.4	.0021	*	.4	1.7	.1848	NS	–1.2	2.4	.0211	*
ANB	2.2	2.5	.0004	*	–1.2	2.1	.0155	*	1	1.9	.0184	*
SNL-NL	.1	2.2	.8549	NS	.6	2.0	.1388	NS	.7	2.1	.1012	NS
SNL-ML	.9	2.6	.1020	NS	–1.8	2.8	.0068	*	–.8	2.7	.1551	NS
SNL-OLs	.3	3.2	.7064	NS	–.1	3.6	.9093	NS	.2	4.3	.8470	NS
Is/SNL	3.3	5.9	.0131	*	6.5	6.3	.0001	*	9.8	8.7	.0001	*
Ii/ML	–1.9	4.2	.0426	*	5.2	6.1	.0006	*	3.2	7.4	.0463	*
Is/Ii	–2.2	8.8	.2403	NS	–9.8	8.2	.0001	*	–12.1	10.8	.0001	*

changed significantly. Measurements that were not statistically significant were SNA, SNL-NL, SNL-ML, SNL-OLs, and Is/Ii. A-point has variability upon location, and the palatal plane, occlusal plane, and mandibular plane did not change significantly between T2 and T1. Also, the interincisal angle did not change significantly during protraction facemask treatment.

Figs. 9–11 show the cephalometric changes 22 months after appliance removal (T3–T2). Significant differences were found in 16 of the 24 variables. Over approximately 2 years, the maxilla continued to develop forward by 1.5 mm, while the mandible moved forward 3.7 mm. Most of the overjet and molar correction, therefore, can be attributed to dental movements. The mean overjet correction decreased by .3 mm and the mean molar correction decreased by .2 mm. Wits decreased 1.4 mm, showing skeletal relapse as well. There was a big difference between the vertical group T2–T1 and T3–T2 (Table 4). In the T2–T1 group, all of the

variables were statistically significant; however, only four out of seven of the variables were statistically significant for the T3–T2 group. The non-significant findings were ANS-Me, overbite, and Msc-NL. Overbite decreased an average of .40 mm and was most likely due to the error mentioned above. Under the angular group, five of the nine values were statistically significant measurements (Table 4). They were ANB, SNL-ML, Is/SNL, Ii/ML, and Is/Ii. This indicates significant incisor angulation change. The mandibular plane angle also changed significantly. In addition, the ANB revealed significant change, but this change was a negative number indicating skeletal relapse. ANB decreased an average of 1.17° during the 22 months following appliance removal.

Figs. 12–14 show the net changes for 9 months of treatment and 22 months of observation (T3–T1). The maxilla moved forward 4.2 mm and the mandible moved forward 4.4 mm. The maxillary incisor rotated labially

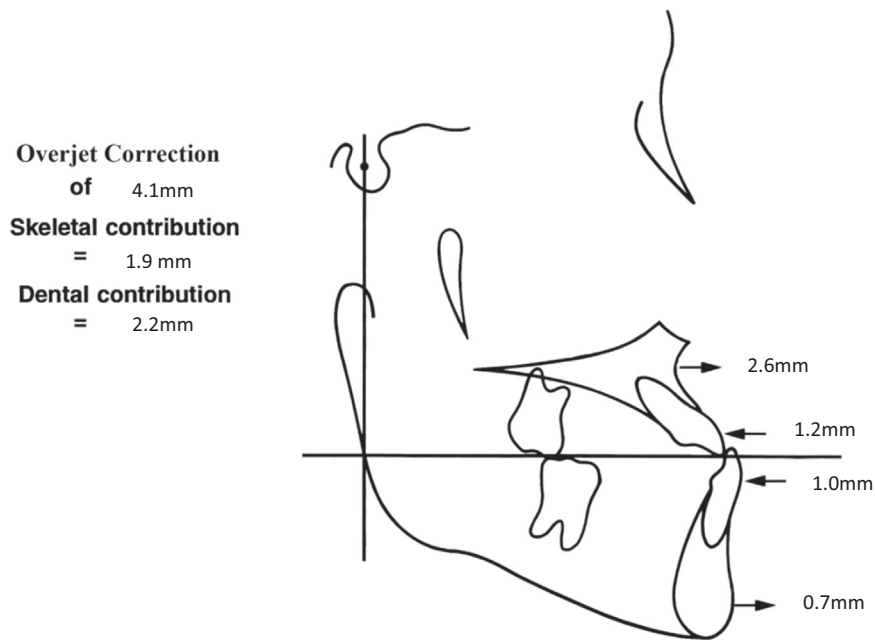


Figure 6. Components of overjet correction T2-T1.

2.9 mm and the mandibular incisor rotated lingually 1.1 mm, resulting in a net overjet correction of 3.8 mm. Mesial movement of the maxillary molars was 1.6 mm, while the

mandibular molars moved distally and average of .1 mm. A net improvement in the molar relationship was 1.7 mm, contributing to a 113% overall dental correction for the

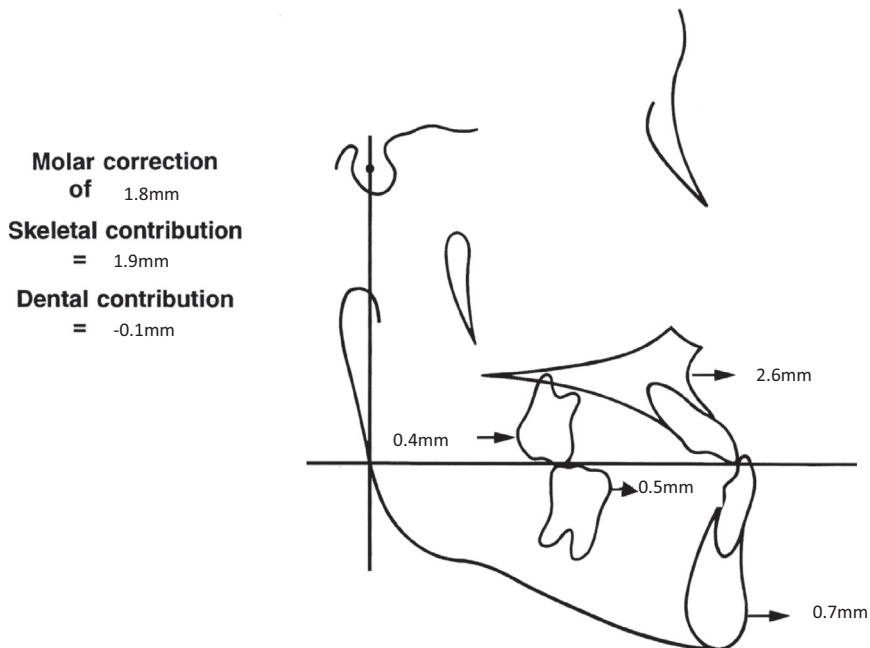


Figure 7. Components of molar correction T2-T1.

mandibular molars. Most of the values found in Table 4 for T3–T1 were statistically significant. This indicates a positive net change during the 9 months of treatment and 22 months of observation. Wits maintained a net correction of 1.6 mm. The measurements that were not statistically significant are as follows: overbite, SNA, SNL-NL, SNL-ML, and SNL-OLs. Due to primary incisor exfoliation and permanent incisor emergence during the study, we discounted overbite changes. Perhaps due to the difficulty in clearly identifying A-point, SNA changes were insignificant. Considering T3–T1, changes in palatal plane, occlusal plane, and mandibular plane were not significant. During the study, SNL-ML, or mandibular plane, was the only measurement plane(s) to show significant changes. These were seen between T3 and T2 (Table 4).

The values for T2–T1, T3–T2, and T3–T1 are listed in Table 4.

Overjet and molar relationship correction

T2–T1

Overjet Correction		Molar Relationship	
Skeletal contribution		Skeletal contribution	
(1) Maxilla	2.6	(1) Maxilla	2.6
(2) Mandible	.7	(2) Mandible	.7
Dental contribution		Dental contribution	
(3) Mx incisor	1.2	(3) Mx molar	.4
(4) Md incisor	-1.0	(4) Md molar	.5

$$\text{Overjet Correction} = \text{Maxilla} + \text{Mx incisor} \\ - \text{Mandible} - \text{Md incisor}$$

$$\text{Overjet Correction} \\ = 2.6 + 1.2 - .7 - (-1.0) = 4.1$$

$$\text{Molar Relationship Correction} = \text{Maxilla} \\ + \text{Mx molar} - \text{Mandible} - \text{Md molar}$$

$$\text{Molar Relationship Correction} \\ = 2.6 + .4 - .7 - .5 = 1.8$$

The amount of skeletal and dental contribution to the overjet and the molar relationship correction for T2–T1 was calculated using the formulas in Table 2. The amount of overjet correction was 4.1 mm. The amount of correction attributed to skeletal movement was 1.9 mm or 46%, and the amount of dental correction was 2.2 mm or 54%. The amount of molar relationship correction was 1.8 mm. The skeletal correction was 105%, leaving -1 mm or -5% attributed to dental movements. Calculations are shown for the overjet and the molar relationship correction above. Diagrams are also provided to illustrate the anterior and posterior movements of the maxilla, mandible, maxillary incisors, mandibular incisor, maxillary molars, and mandibular molars (Figs. 6 and 7). The pitchfork-type analysis describing the skeletal and dental components of overjet and molar correction is shown in Fig. 8.

T3–T2

Overjet Correction		Molar Relationship	
Skeletal contribution		Skeletal contribution	
(1) Maxilla	1.5	(1) Maxilla	1.5
(2) Mandible	3.7	(2) Mandible	3.7
Dental contribution		Dental contribution	
(3) Mx incisor	1.8	(3) Mx molar	1.4
(4) Md incisor	-1	(4) Md molar	-6

$$\text{Overjet Correction} = \text{Maxilla} + \text{Mx incisor} \\ - \text{Mandible} - \text{Md incisor}$$

$$\text{Overjet Correction} \\ = 1.5 + 1.8 - 3.7 - (-1) = -.3$$

$$\text{Molar Relationship Correction} = \text{Maxilla} \\ + \text{Mx molar} - \text{Mandible} - \text{Md molar}$$

$$\text{Molar Relationship Correction} \\ = 1.54 + 1.31 - 3.7 - (-.61) = -.24$$

The amount of skeletal and dental contribution to the overjet and the molar relationship correction for T3–T2 was calculated using the formulas above. The amount of overjet correction was -.3 mm. The amount of correction

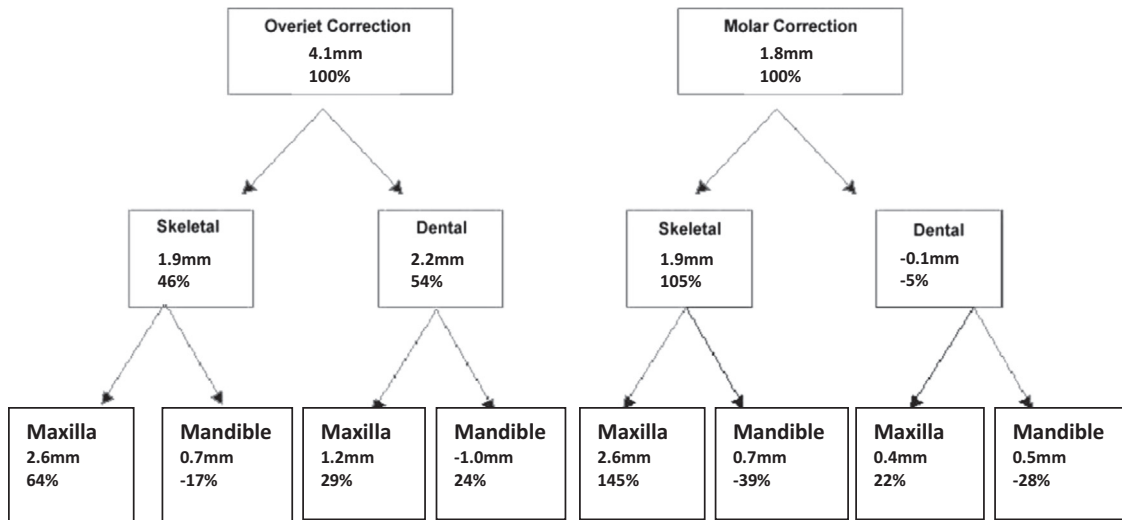


Figure 8. Pitchfork-type analysis for overjet and molar correction T2-T1.

attributed to skeletal movement was -2.2 mm or -733%, and the amount of dental correction was 1.9 mm or 633%. The amount of molar relationship correction was -2 mm. The skeletal correction was -2.2 mm, or -1100%; leaving 2.0 mm or 1000% attributed to dental movements. Calculations are shown for the overjet

and the molar relationship correction above. Diagrams are also provided to illustrate the anterior and posterior movements of the maxilla, mandible, maxillary incisors, mandibular incisors, maxillary molars, and mandibular molars (Figs. 9 and 10). A pitchfork-type analysis describing the skeletal and dental com-

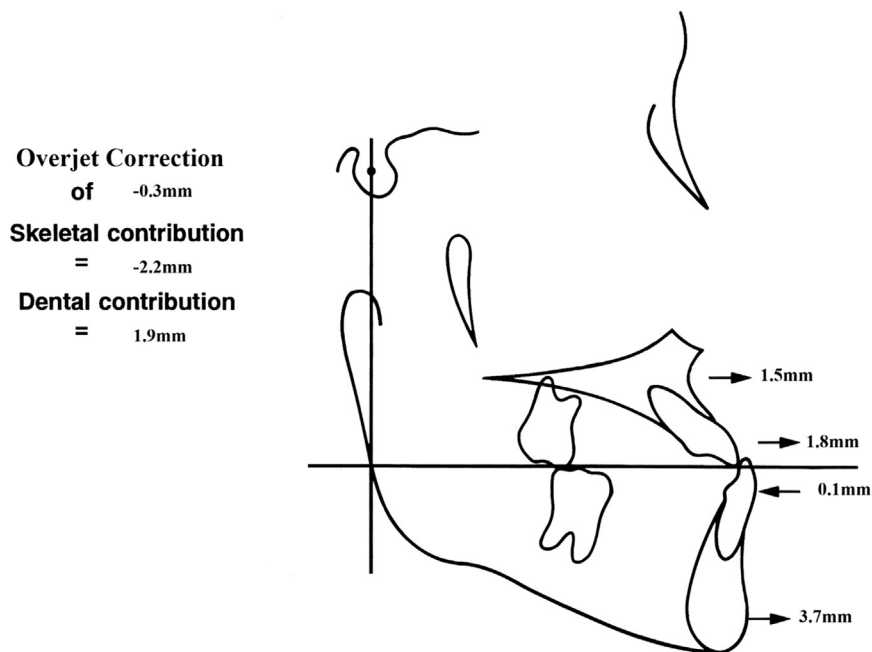


Figure 9. Components of overjet correction T3-T2.

ponents of overjet and molar correction is shown in Fig. 11.

T3-T1

Overjet Correction		Molar Relationship	
Skeletal contribution		Skeletal contribution	
(1) Maxilla	4.2	(1) Maxilla	4.2
(2) Mandible	4.4	(2) Mandible	4.4
Dental contribution		Dental contribution	
(3) Mx incisor	2.9	(3) Mx molar	1.6
(4) Md incisor	-1.1	(4) Md molar	-1

$$\text{Overjet Correction} = \text{Maxilla} + \text{Mx incisor} - \text{Mandible} - \text{Md incisor}$$

$$\text{Overjet Correction} = 4.2 + 2.9 - 4.4 - (-1.1) = 3.8$$

$$\text{Molar Relationship Correction} = \text{Maxilla} + \text{Mx molar} - \text{Mandible} - \text{Md molar}$$

$$\text{Molar Relationship Correction} = 4.2 + 1.6 - 4.4 - (-1) = 1.5$$

The amount of skeletal and dental contributions for T3-T1 net overjet and net molar relationship correction were calculated using the formulas in Table 2. This T3-T1 shows the net change that occurred over the length of the study, which was 31 months. The amount of net overjet correction was 3.8 mm. This measurement is the result of the dental incisor correction being 4 mm while the skeletal contributions were -.2 mm. Reviewing the dental movements, the maxillary incisors moved forward 2.9 mm and the mandibular incisors moved backward 1.1 mm, resulting in a total dental correction of 4 mm. The net molar correction was 1.5 mm. The maxillary molar moved forward 1.6 mm and the mandibular molar moved backward .1 mm, resulting in a net dental correction for the molars of 1.7 mm. Diagrams and illustrations of these findings are found in Figs. 12 and 13. A pitchfork-type analysis describing the net skeletal and dental contributions to overjet and molar relationship correction is shown in Fig. 14.

Discussion

Previous investigators including Saadia et al., Turley, Baccetti et al., and Kapust have reported more effective and efficient treatments for younger patients. The ages in the early treatment groups ranged from 3 to 7 years. They found that changes for the younger age groups were nearly twice that of "older" groups ages 10 and 14.^{13,14} Our age ranges were a bit different from previously reported data. The youngest treated patient in this study was 4 years 4 months with an average of 6 years 2 months. The oldest age was 10 years 4 months, which falls within the classified "older" group for previously completed research. Although the oldest age group in this study was over 10 years of age, the CVM was "1," indicating the study group had similar skeletal ages.

Guyer et al. found longitudinal data on Class III subjects and showed them to have an average maxillary growth of less than 1 mm/year and mandibular growth of 3-4.5 mm/year. This study showed an average maxillary growth of 1.6 mm/year and an average mandibular growth of 1.7 mm/year. This shows a vastly different skeletal growth pattern between our treated group and the control study conducted by Guyer et al.¹³

Franchi et al. investigated treatment timing for treatment with expansion and facemask appliances. The authors compared an early treatment group that included subjects in the deciduous and early mixed dentition with a late treatment group that included the subjects with erupting permanent premolars and canines. The authors found that a significant maxillary movement of about 2 mm was maintained in the early treatment group.¹ In our study, results following active treatment showed a forward movement of the maxilla of about 2.6 mm, which supports previous findings. The mandibular forward movement was .7 mm during active treatment. This calculates to an average mandibular growth of less than 1 mm/year. Comparing this to the average mandibular growth in subjects not undergoing treatment, which is approximately 3-4.5 mm of mandibular growth per year, significant differences can be found. The net changes found in this study showed a forward movement of the maxilla of 4.2 mm between T1 and T3 time points. The mandible, however, did "catch up" with the maxilla, having a total forward movement of 4.4 mm. The mandible outgrew the

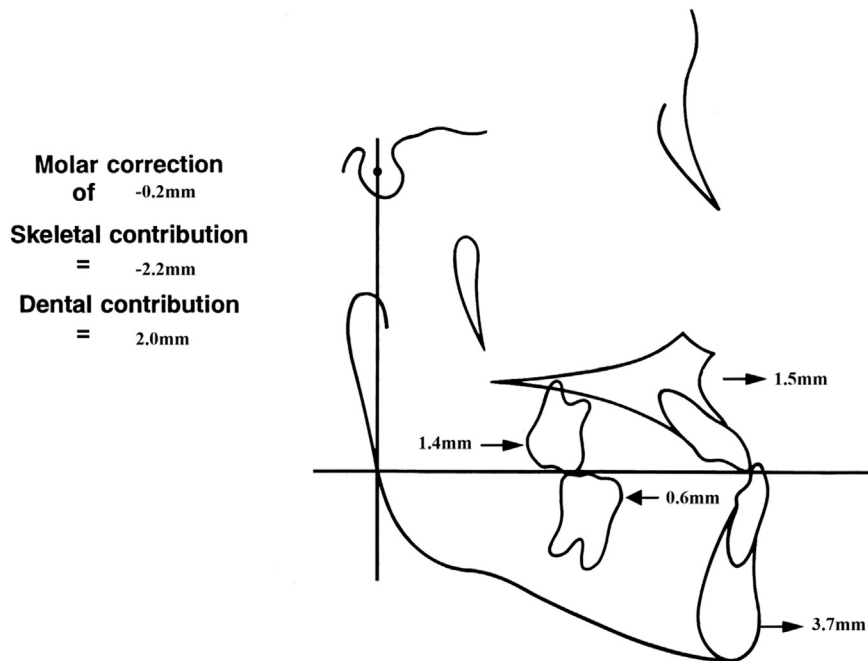


Figure 10. Components of molar correction T3-T2.

maxilla, but only slightly, indicating that a maxillary orthopedic change was achieved and maintained.

Franchi et al. also found that early treatment maintained a maxillary/mandibular skeletal relationship within 1 mm because of the significant favorable skeletal contributions of the maxilla and the mandible from RME/FM treatment.⁸ This study also supports these previous findings because the total skeletal differential in the growth of the

maxilla and the mandible over the 31 months of observation was that the mandible outgrew the maxilla by only .2 mm.

The average treatment age for this research group was 6 years 2 months at the beginning of treatment. The 23 samples ranged from 4 years 4 months to 10 years 4 months. During treatment, the overjet correction attained was 4.1 mm. Most of this correction was maintained

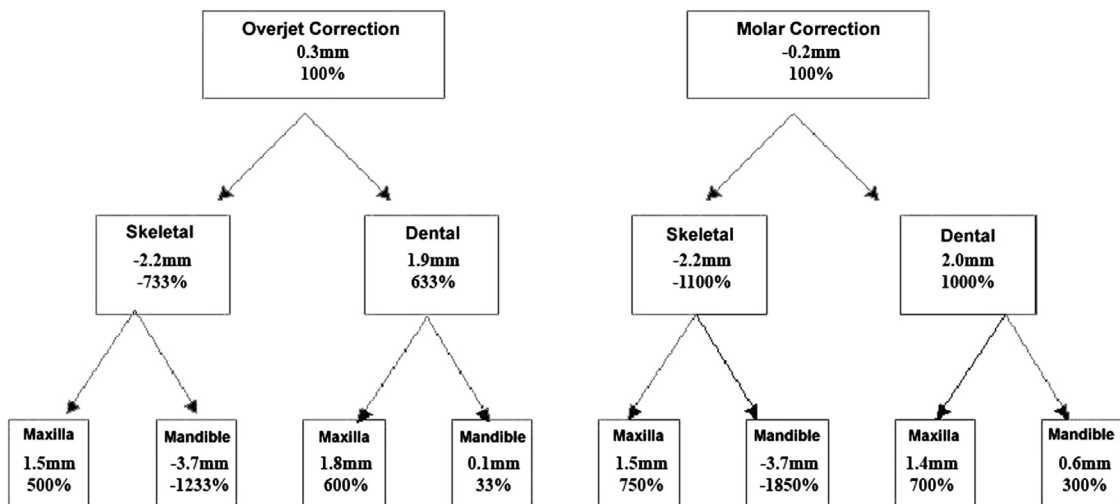


Figure 11. Pitchfork-type analysis for overjet and molar correction T3-T2.

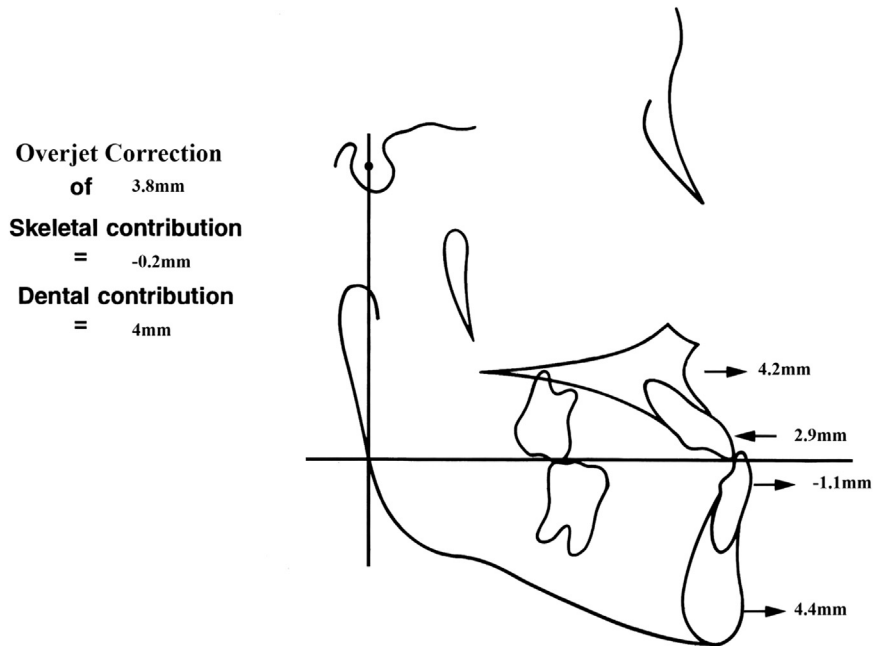


Figure 12. Components of overjet correction T3-T1.

with a final overjet correction of 3.8 mm. This shows that the achieved results were stable over the approximate 2 year post-treatment time span. The molar correction achieved during

treatment was 1.8 mm and the molar correction 22 months later was an average of 1.5 mm. The molar correction was stable after the appliances were removed over approximately 2 years.

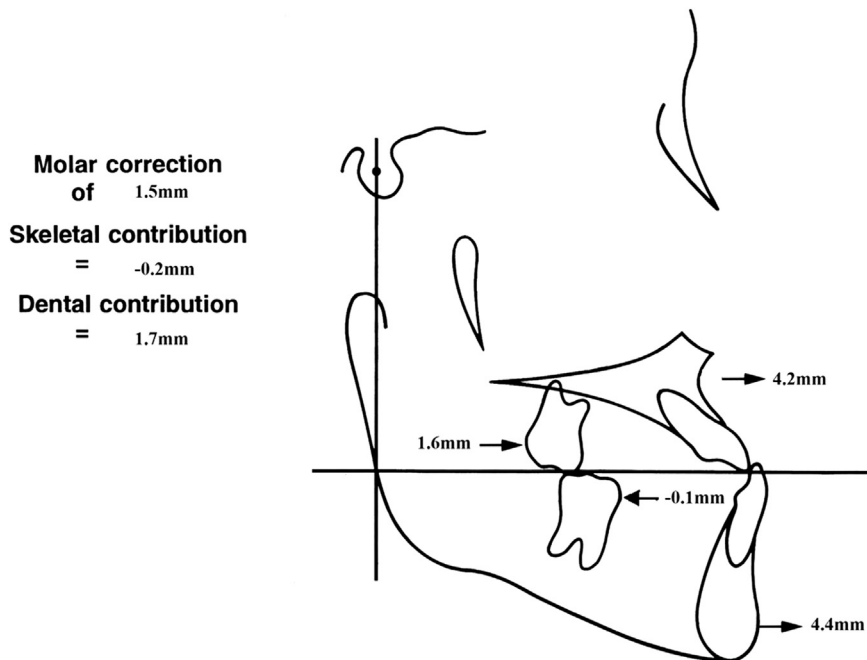


Figure 13. Components of molar correction T3-T1.

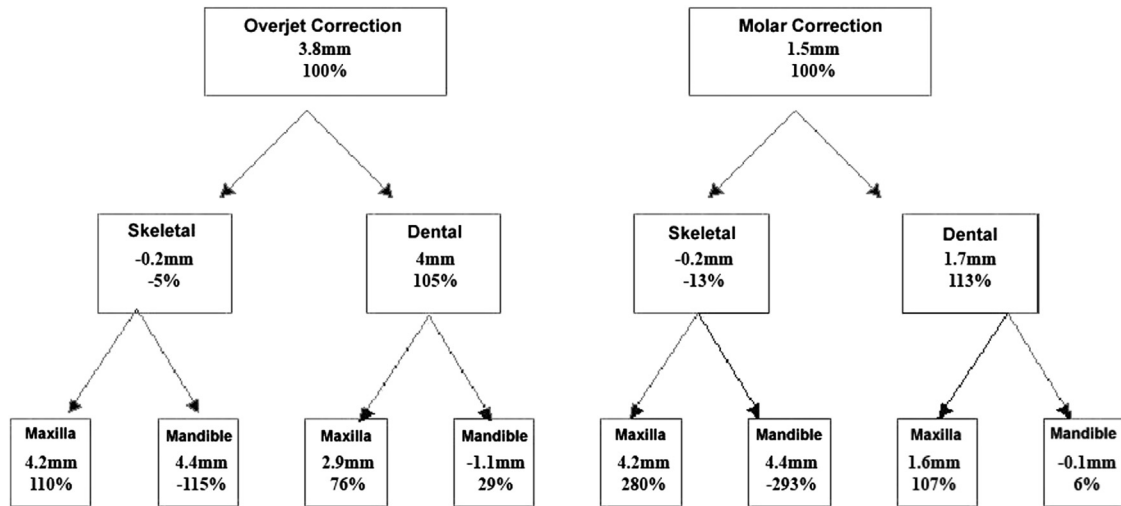


Figure 14. Pitchfork-type analysis for overjet and molar correction T3-T1.

The radiographs were traced by the same examiner to reduce error. The method of cephalometric analysis by Pancherz¹² was reliable, and the error that did occur was within acceptable parameters. The angular measurements showed that the palatal plane, occlusal plane, and mandibular plane did not change significantly during treatment. The only significant change occurred between T2 and T3 time points with the mandibular plane. Results showed a decrease in the mandibular plane angle, which increased again for the time points T1 to T3. This indicates that the mandibular plane Angle changed with treatment, but reverted back toward pre-treatment averages by the 2nd year post-treatment cephalogram.

Skeletal maturation and age differentiation was not addressed in this project because the entire study sample size had a CVM I skeletal age for time point T1. There would have been no difference in the results, so all patients were pooled together.

The research conducted evaluated an active treatment time of 9 months and a follow-up of approximately 2 years after active treatment. This was a long-term observational study that was able to show skeletal and dental stability over time. The Wits measurement before treatment was -4.2 and was -2.5 after 31 months of treatment and observation. This shows that the skeletal correction achieved at a young age was maintained over the 2 years of observation. Results support previous research advocating early treatment for Class III malocclusions.

Conclusions

Significant overjet and overbite corrections can be obtained with maxillary protraction in the primary or early mixed dentition. The overjet and the molar relationship correction were stable 2 years following treatment primary by dentoalveolar compensation to skeletal changes.

Reference

1. Franchi L. Postpubertal assessment of treatment timing for maxillary expansion and protraction therapy followed by fixed appliances. *Am J Orthod Dentofacial Orthop.* 2004;126(5):555-568.
2. Proffit WR, Fields HW Jr. *Contemporary Orthodontics*. 3rd ed, St Louis, MO: Mosby; 2000.
3. McNamara JA Jr, Brudon WL. *Orthodontics and Dentofacial Orthopedics*. Ann Arbor, MI: Needham Press; 2001.
4. Baccetti T. Skeletal effects of early treatment of Class III malocclusion with maxillary expansion and facemask therapy. *Am J Orthod Dentofacial Orthop.* 1998;113(3):333-343.
5. Vaik HS. Clinical results of maxillary protraction in Korean children. *Am J Orthod Dentofacial Orthop.* 1995;108(5):583-592.
6. Merwin D, Ngan P, Hagg U, Yiu C, Wei SH. Timing for effective application of anteriorly directed orthopedic force to the maxilla. *Am J Orthod Dentofacial Orthop.* 1997;112(2):292-299.
7. Kapust AJ, Sinclair PM, Turley PK. Cephalometric effects of facemask/expansion therapy in Class III children: a comparison of three age groups. *Am J Orthod Dentofacial Orthop.* 1998;113(2):204-212.
8. Saadia M, Torres E. Sagittal changes after maxillary protraction with expiation in Class III patients in the primary, mixed, and late mixed dentitions: a longitudinal retrospective study. *Am J Orthod Dentofacial Orthop.* 2000;117(8):669-680.

9. Baccetti T, Franchi L, McNamara JA Jr. Treatment and post-treatment craniofacial changes after rapid maxillary expansion and facemask therapy. *Am J Orthod Dentofacial Orthop.* 2000;118(4):404–413.
10. Cha KS. Skeletal changes of maxillary protraction in patients exhibiting skeletal Class III malocclusion: a comparison of three skeletal maturation groups. *Angle Orthod.* 2003;73(1):26–35.
11. Bjork A. *The Face in Profile: An Anthropological X-ray Investigation of Swedish Children and Conscripts.* Lund: Berlingska Boktryckeriet. 1947;40:58.
12. Pancherz H. The mechanism of Class II correction in Herbst appliance treatment, a cephalometric investigation. *Am J Orthod.* 1982;82(1):107–113.
13. Baccetti T. Craniofacial changes in Class III malocclusion as related to skeletal and dental maturation. *Am J Orthod Dentofacial Orthop.* 2007;132(2):171–178.
14. Saadia M, Torres E. Sagittal changes after maxillary protraction with expansion in Class III patients in the primary, mixed and late mixed dentitions: a longitudinal retrospective study. *Am J Orthod Dentofacial Orthop.* 2000;117(6):669–680.